

MANAGEMENT OF ENDODONTICALLY CHALLENGED UPPER MOLARS.

¹Janus Raji, ²Sunil Malhan, ³Gursandeep Kaur Sandhu, ⁴Himanshu Sood, ⁵Danish Prabhkar

¹Post Graduate student (3rd Year), Department of Conservative Dentistry & Endodontics,
Desh Bhagat Dental College & Hospital, Mandi Gobindgarh, Punjab.

²HOD, Department of Conservative Dentistry & Endodontics,
Desh Bhagat Dental College & Hospital, Mandi Gobindgarh, Punjab.

³Professor, Department of Conservative Dentistry & Endodontics,
Desh Bhagat Dental College & Hospital, Mandi Gobindgarh, Punjab.

⁴Reader, Department of Conservative Dentistry & Endodontics,
Desh Bhagat Dental College & Hospital, Mandi Gobindgarh, Punjab.

⁵PG student (3rd Year), Department of Conservative Dentistry & Endodontics,
Desh Bhagat Dental College & Hospital, Mandi Gobindgarh, Punjab.

Corresponding Author:

Janus raji, Post Graduate student (3rd Year), Department of Conservative Dentistry & Endodontics,
Desh Bhagat Dental College & Hospital, Mandi Gobindgarh, Punjab.
Email id: janus22raji@gmail.com Phn. No.: 9383427761

Abstract

The root canal aberrations and variations in maxillary second permanent molars is a constant challenge and successful endodontic management with latest adjuncts decreases the failure of missing a canal. Detection of all the root canals and their disinfection is important for proper healing and long-term survival of the tooth. It is considered that fusion of the teeth can occur anywhere and that the location of fusion can be in any of the cervical, middle, or apical thirds or in some combination. This case report discusses and highlights the management of endodontically challenged upper molars.

Keywords: Endodontic management, Fusion, Molars, root canal.

INTRODUCTION

Due to their complex root canal anatomy, endodontic management of maxillary molars exhibits a persistent challenge.¹ A major cause of root canal failure is the inability to locate, debride, or properly fill all root canal system canals.² A thorough understanding of the root canal system, and its frequent variations along with diagnosis and treatment planning, is an absolute requirement for successful endodontic treatment.³ The anatomical characteristics of permanent maxillary molars are complex and are generally described as teeth with three roots: Two buccal root canals and one palatal root canal.⁴ In recent years, two palatal and two mesiobuccal root canals have been reported separately.⁵ The incidence of a second mesiobuccal root canal (MB2) is 58.4% in Asians.⁶ The incidence of a second distobuccal canal is between 1.6% and 9.5%.⁷ The anatomy and morphology of roots in the permanent maxillary first molar and root canals vary greatly. Except for three roots, other variations include two,⁸ four, five,⁹ six,¹⁰ seven,¹¹ and eight¹² root canals as well as O-shaped canals¹³ within individual roots.

To characterize the type of root fusion of the maxillary molars, the classification of Zhang et al.¹⁴ was used.

- Type 1: Mesiobuccal (MB) root fused with distobuccal (DB) root.
 - Type 2: MB root fused with palatal (P) root.
 - Type 3: DB root fused with P root.
 - Type 4: MB root fused with DB root and P root or P root with MB and DB roots (proximal groove).
 - Type 5: P root fused with MB and DB roots (vestibular groove).
 - Type 6: P, MB, and DB roots fused as a cone-shaped root
- Case report

A 35-year-old female patient with no medical history reported to the Department of Conservative Dentistry and Endodontics of the Desh Bhagat Dental College & Hospital, Mandi Gobindgarh with pain in the upper right back tooth region for one week. Patient's History was taken and Clinical examination was performed. He had a spontaneous and intermittent toothache that had worsened, particularly at night and relieved by analgesics. The diagnosis based on clinical examination, X-ray imaging. On examining the tooth was tender to percussion. Cold test revealed no response and delayed response with electric pulp test. The tooth was diagnosed with irreversible pulpitis. The tooth was not mobile, and periodontal tooth probing was within physiological limits. On examination of the intra-oral periapical radiograph morphological variation of the root canal anatomy was not evident; however it revealed the presence of a fused root (figure 1).

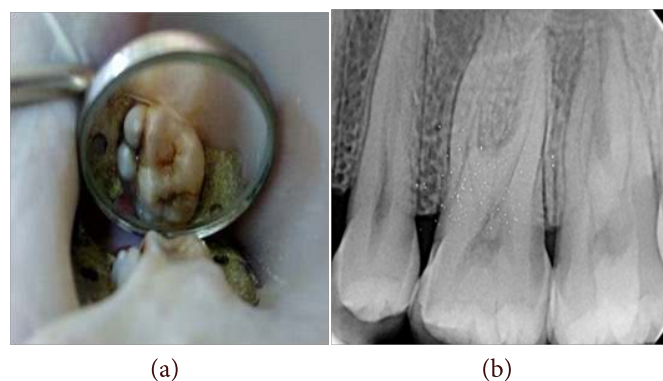


Fig No. 1: (a) pre-operative picture (b) pre operative radiograph

Under rubber dam isolation, access cavity was prepared with endo access bur after administering local anesthesia (Fig.2). Working length was determined with the help of ISO 10 K-file. DG 16 endodontic explorers revealed MB2 as a small haemorrhagic pin point palatal to the main MB orifice and accessory palatal canal distal to the main palatal canal. The access cavity preparation revealed the orifices of three canals: one mesiobuccal, one distobuccal and one palatal. Working length was determined using apex locator and confirmed with radiograph (Fig.3). Cleaning and shaping were performed using k files till 30 no. file and for mesiobuccal and distobuccal canals and whereas palatal canals are enlarged till 40.no files along with 17% EDTA gel. Irrigation was done using 3% sodium hypochlorite solution throughout the procedure.



Fig No.2: Photograph showing the access cavity preparation

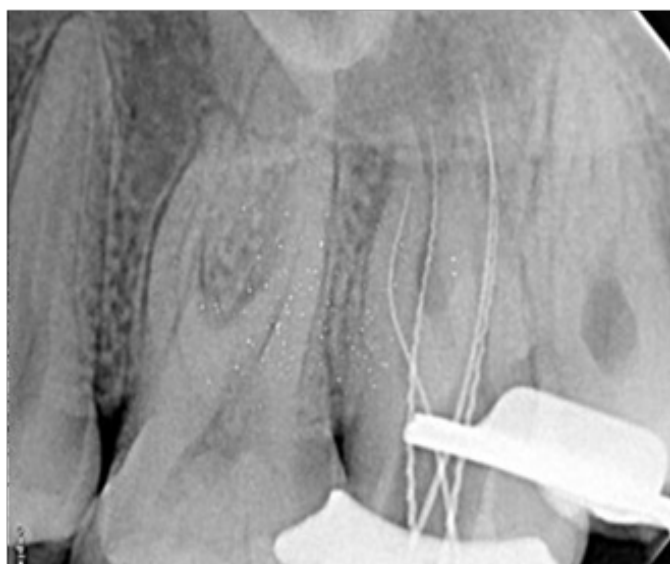


Fig No.3: Radiograph with working length.

Master cones were selected corresponding to the size and taper of the last file used to the working length, which was confirmed radiographically. The canals were dried with absorbent paper points, and obturation was performed using gutta-percha (Fig.5).

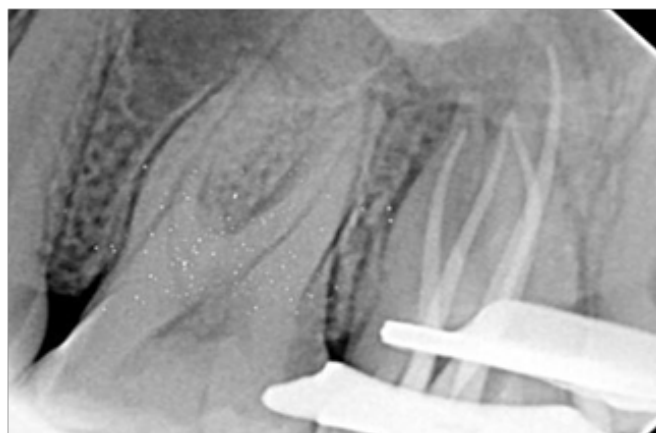


Fig No.4: Radiograph with master cone

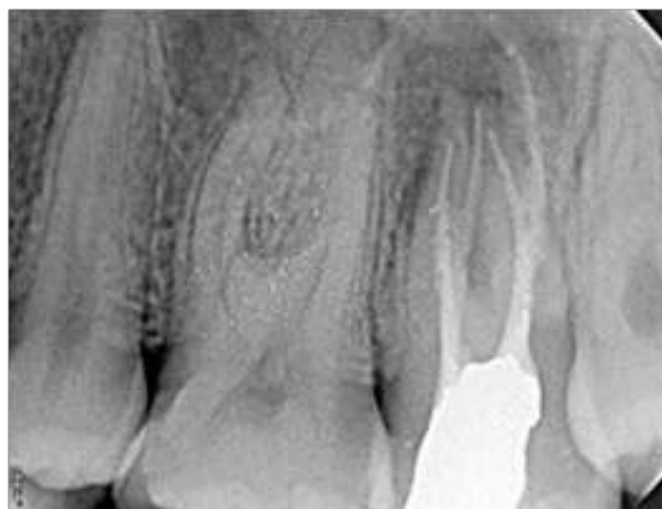

Fig No.5: Radiograph after obturation

Discussion

Maxillary molars have three roots (96.2%) two buccal and one palatal.¹⁵ The possible variations in the external root morphology in these teeth are extra root, fused roots or a single conical root. A tooth with a single conical root usually has a single large canal¹⁶; however, teeth with fused roots will definitely have more than one canal. Due to the extensive use of magnification and illumination aids, the incidence of extra roots and/or canals in the maxillary molars and their management has been extensively discussed in the literature.^{17,18}

So far the number of canals in maxillary second molar have been reported to vary from 1-6.¹⁹ Moreover occurrence of fused roots is more prevalent in maxillary second molars (42%).²⁰ According to Percora and his researchers, among a total of 744 maxillary first, second and third molars observed, complete separation of all three roots was 86.4%, 75.9%, 18.8 % respectively. Whereas fusion of all three roots and fusion of only the buccal roots was 0.07%, 1.8%, 17.4% and 7.9%, 20.4%, 28.9% respectively.²¹

Understanding the anatomical variations of the root canal system is essential to the success of endodontic treatment.²² The main goal of this treatment is to prevent apical pathosis and promote healing. One reason for failure is the inability to clean, negotiate, or obturate all existing root canals. Root canals may not be cleaned because the dentist fails to detect their presence.²³ The canals of fused roots are more complex than those of separate roots, which may increase the failure rate of root canal treatment.

Fusion has been defined as the deposition of cementum on the radicular surface from the CEJ to the apex.²⁴ The term “fused root” is also defined as two or more roots that are united through deposits formed in the course of an individual's life or as the result of an alteration in the development of the Hertwig epithelial root sheath in the furcation area.¹⁴ It is considered that fusion of the teeth can occur anywhere and that the location of fusion can be in any of the cervical, middle, or apical thirds or in some combination thereof.²⁵ The major difference in the prevalence of molars with fused roots between upper and lower teeth is due to the fact that upper teeth have more roots, yielding a greater possibility of different combinations compared to the lower molars.²⁶

Careful location and negotiation of the canals should be carried out for successful management. This case highlights the ultimate importance of mastering the root canal anatomy of the maxillary molars in nonsurgical endodontic therapy.

Conclusion

This case report discusses the endodontic management of an unusual case of a maxillary second molar with fused mesio-buccal and distobuccal canals. The type of root fusion observed here is the mesio-buccal and disto buccal canals. Failure to locate and treat additional canals can adversely affect the outcome of endodontic therapy. Detection of all the root canals and their disinfection is important for proper healing and long-term survival of the tooth.

References

1. Buhrley LJ, Barrows MJ, BeGole EA, Wenckus CS. Effect of Magnification on Locating the MB2 Canal in Maxillary Molars. *J Endod.* 2002 Apr;28(4):324-7
2. Frank J, Vertucci FJ. Root canal morphology and its relationship to endodontic procedures. *Endodontic Topics.* 2005;10(1):3-29.
3. Friedman S. Prognosis of initial endodontic therapy. *Endod Topics.* 2002;2(1):59-88.
4. Bornstein MM, Wasmer J, Sendi P, Janner SF, Buser D, von Arx T. Characteristics and dimensions of the Schneiderian membrane and apical bone in maxillary molars referred for apical surgery: a comparative radiographic analysis using limited cone beam computed tomography. *J Endod.* 2012;38:51-57.
5. Asghari V, Rahimi S, Ghasemi N, Talebzadeh B, Norlouoni A. Treatment of a Maxillary First Molar with Two Palatal Roots. *Iran Endod J.* 2015;10:287-289.
6. Martins JNR, Gu Y, Marques D, Francisco H, Caramès J. Differences on the Root and Root Canal Morphologies between Asian and White Ethnic Groups Analyzed by Cone-beam Computed Tomography. *J Endod.* 2018;44:1096-1104.
7. Sert S, Bayirli GS. Evaluation of the root canal configurations of the mandibular and maxillary permanent teeth by gender in the Turkish population. *J Endod.* 2004;30:391-398.
8. Sharma S, Mittal M, Passi D, Grover S. Management of a maxillary first molar having atypical anatomy of two roots diagnosed using cone beam computed tomography. *J Conserv Dent.* 2015;18:342-345.
9. Schryvers A, Govaerts D, Politis C, Lambrechts P. Endodontic management of a maxillary first molar with two palatal roots: A case report. *Aust Endod J.* 2019;45:420-425.
10. Ferguson DB, Kjar KS, Hartwell GR. Three canals in the mesiobuccal root of a maxillary first molar: a case report. *J Endod.* 2005;31:400-402.
11. de Almeida-Gomes F, Maniglia-Ferreira C, Carvalho de Sousa B, Alves dos Santos R. Six root canals in maxillary first molar. *Oral Surg Oral Med Oral Pathol Oral Radiol Endod.* 2009;108:e157-e159.
12. Badole GP, Warhadpande MM, Sheno PR, Lachure C, Badole SG. A rare root canal configuration of bilateral maxillary first molar with 7 root canals diagnosed using cone-beam computed tomographic scanning: a case report. *J Endod.* 2014;40:296-301.
13. Kottoor J, Velmurugan N, Surendran S. Endodontic management of a maxillary first molar with eight root canal systems evaluated using cone-beam computed tomography scanning: a case report. *J Endod.* 2011;37:715-719.
14. Ferguson DB, Kjar KS, Hartwell GR. Three canals in the mesiobuccal root of a maxillary first molar: a case report. *J Endod.* 2005;31:400-402.
15. BM Cleghorn, WH Christie, CSC Dong. Root and root canal morphology of the human permanent maxillary first molar: a literature review. *J Endod.* 2006;32:813-21.
16. LRG Fava, I Weinfeld, FP Fabri, CR Pais. Four second molars with single roots and single canals in the same patient. *Int Endod J.* 2000;33:138-42.
17. K Karthikeyan, S Mahalaxmi. New nomenclature for extra canals based on four reported cases of maxillary first molars with six canals. *J Endod.* 2010;36:1073-78.
18. JVB Barbizam, RG Riberiro, MT Filho. Unusual anatomy of permanent maxillary molars. *J Endod.* 2004;30:668-71.
19. C Zeng, Y Shen, X Guan, X Wang, M Fan, Y Li. Rare root canal configuration of bilateral maxillary second molars using cone beam computed tomographic scanning. *J Endod.* 2016;42:673-77.
20. Q Zhang, H Chen, B Fan, W Fan, JL Gutmann. Root and root canal morphology in maxillary second molar with fused root from a native Chinese population.
21. JD Pecora, JB woelfel, MDS Neto. Morphologic study of the maxillary molars. *Braz Dent J.* 1991;2:45-50.
22. Ahmad IA, Al-Jadaa A. Three root canals in the mesiobuccal root of maxillary molars: case reports and literature review. *J Endod.* 2014;40:2087-2094.
23. Thomas RP, Moule AJ, Bryant R. Root canal morphology of maxillary permanent first molar teeth at various ages. *Int Endod J.* 1993;26:257-267.
24. Tian XM, Yang XW, Qian L, Wei B, Gong Y. Analysis of the root and canal morphologies in maxillary first and second molars in a Chinese population using cone-beam computed tomography.
25. Yang ZP, Yang SF, Lee G. The root and root canal anatomy of maxillary molars in a Chinese population. *Endod Dent Traumatol.* 1988;4:215-218.
26. Martins JN, Mata A, Marques D, Anderson C, Caramès J. Prevalence and characteristics of the maxillary C-shaped molar. *J Endod.* 2016;42:383-389.