

## A COMPARATIVE STUDY TO CHECK THE EFFICACY OF PRF IN TISSUE REGENERATION AFTER SURGICAL EXTRACTION OF IMPACTED MANDIBULAR THIRD MOLARS

Preet Kanwal Singh Ahluwalia<sup>1</sup>, Gita Chopra<sup>2</sup>, Danish Sharma<sup>3</sup>, Damandeep Kaur Mander<sup>4</sup>

HOD, department of Oral & Maxillofacial Surgery, National Dental College & Hospital, Dera Bassi<sup>1</sup>

Senior resident & consultant, Bajwa Multispecialty hospital, Amritsar<sup>2</sup>

Consultant, Fortis Escort, Amritsar<sup>3</sup>

Senior lecturer, department of Oral & Maxillofacial Surgery, National Dental College & Hospital, Dera Bassi<sup>4</sup>

### Abstract

**Aim:** The study conducted aimed at PRF efficacy in the soft tissue healing and bone regeneration after surgical removal of impacted mandibular 3rd molars.

**Material and Method-** This study includes 16 patients, who were randomly selected in the Department of Oral and Maxillofacial Surgery. Patients who were selected had bilaterally impacted third molars and were indicated for surgical extractions bilaterally.

The post extraction sockets were divided into 2 groups, Group A (study group) was grafted with PRF and then primarily closed and Group B (control group) was primarily closed without any PRF graft.

Postoperatively patients were reviewed for soft tissue healing on 1st, 3rd and 7th day and bone healing on 1st, 2nd and 3rd month.

**Results:** It was found that soft tissue healing was better in the group A as compared to group B. The difference in trabecular pattern showed significant increase in healing speed at the end of third month postoperatively in study group as compared to control group.

**Conclusion:** In this study, the clinical and radiological findings clearly indicate that PRF can be used as a sole graft material to improve soft tissue healing and bone regeneration.

### Introduction

Third molar is the last tooth to erupt, so it may readily become either impacted or displaced if there is insufficient room for it within the dental arch. One of the major concerns in Surgery is the regeneration of bony defects resulting after various surgical procedures which may cause severe aesthetic and functional problems. In such cases the use of bone grafts, derivatives or bone substitutes are indicated to promote healing and bone regeneration<sup>1</sup>.

Different bone grafts used for enhancing the rate of bone formation and augmentation of the bone quality include autografts, allografts, xenografts or alloplastic bone substitutes. Autogenous bone grafts till date are the “gold standard” for bone grafting as they alone offer the three necessary components for bone repair- osteoinduction, osteogenicity and an osteoconductive matrix.

Platelets play a key role in wound healing. There is release of certain substances from platelets that promotes tissue repair, angiogenesis, inflammation, immune response, bone regeneration, stimulation of cell migration, differentiation and repair<sup>2</sup>.

PRF belongs to a new generation of platelet concentrates customized to a preparation without

biochemical blood handling. It is a second-generation platelet concentrate, prepared from centrifuged blood, is an autogenous source of various growth factors obtained by sequestering and concentrating drawn venous blood. Platelet rich fibrin enhances wound healing by increasing the availability of critical growth factors that are released by platelet degranulation which in turn also help in accelerated bone regeneration<sup>3</sup>.

### Materials and Methods

Sixteen patients with bilaterally impacted mandibular third molars, were randomly selected from those reporting to the Outpatient Department of Oral and Maxillofacial Surgery, National Dental College And Hospital, Dera Bassi, Punjab. All the patients were informed regarding the surgical procedure and consent was obtained before the surgery. The present comparative, prospective study was conducted as a controlled clinical trial using split mouth design (in vivo), where in the effect of PRF grafted extraction socket of impacted mandibular third molar was compared with non-grafted extraction socket of impacted mandibular third molar in the same patient.

The extractions sockets were divided into two groups.

Group 1- The socket was grafted with PRF (study group) and primarily closed.

Group 2- The socket was not grafted with PRF (control group) and primarily closed.

Soft Tissue Healing was evaluated using Landry<sup>4</sup> et. al. index. Clinical evaluation was done on 1st, 3rd and 7th postoperative days. Bone healing was assessed radiographically using a standard reproducible Intraoral Periapical Radiograph (IOPA) with a film holding device, exposure parameters being same. IOPA radiographs were taken immediately post operatively, by the end of first, second and third month. A particular area was selected on IOPA films which included new bone and adjacent old bone to compare the new bone formation. The bone healing criteria and the scoring system in this study were based on a modification<sup>5</sup> of the method used by Kelley<sup>6</sup> et al. in which base line radiographic score was taken as 0. The gross variance from baseline radiological score is represented by +2 or -2 and the significant variation from normal is +1 or -1.

#### Prf Preparation Protocol

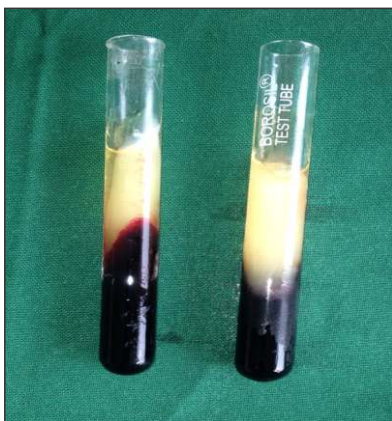
Dohan and Choukroun<sup>2</sup> et al suggested that PRF is derived from a natural and progressive process of

polymerization that occurs during centrifugation of blood. The absence of anticoagulant activates most platelets of the blood sample in contact with the tube walls and the release of the coagulation cascade in a few minutes. Therefore, blood collection and its transfer to centrifugator is important, as with delay, the fibrin will polymerize in a diffuse way in the tube and only a small blood clot without consistency will be obtained. To get the PRF clot which is clinically useful, proper handling and accurate protocol is required. The results of the study by Chen Yao Su<sup>7</sup> et al supported that preparing the PRF immediately before using it to allow for continuous release of growth factors over the subsequent 300 minutes.

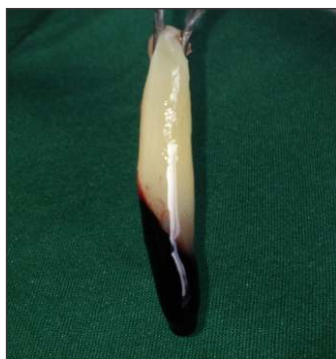5-10 ml blood was drawn, according to the size of defect, from a peripheral vein. Blood was collected in 10 ml pre sterilized test tubes without an anticoagulant and centrifuged immediately at 3000 rpm (approx) for 10 minutes.

As a Result, test tube consists of following three layers:

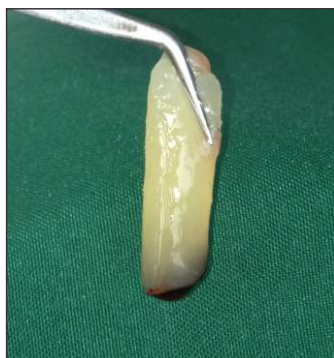1. Upper most layer consists of Acellular Platelet poor plasma.
2. Middle layer consists of PRF clot .
3. Lower most layer consists of RBC's.



**Fig.1: Blood immediately after centrifugation. Three layers representing top layer as platelet poor plasma, middle layer as PRF and bottom layer as red blood cells.**



**Fig. 2: PRF Clot with RBC layer.**

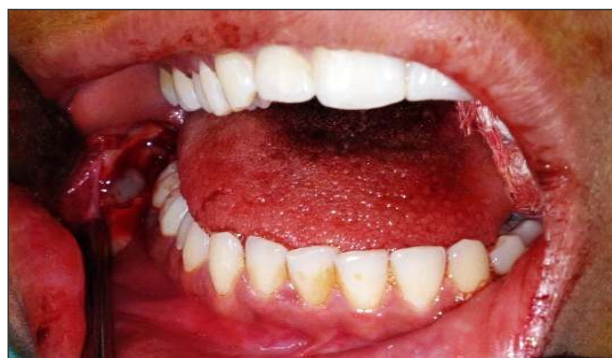


**Fig.3: PRF Layer separated from RBC layer.**

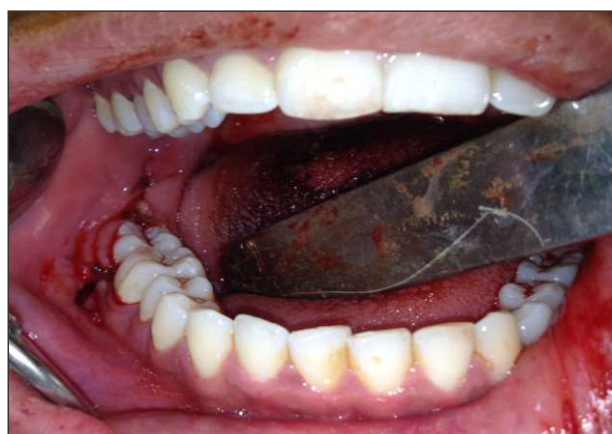### Surgical procedure

After surgical extraction of bilateral third molars in a single visit all patients were given antibiotics Cap.amoxicillin (500 mg every 8 hrs for 5days) or Tab.Erythromycin (500 mg every 6 hrs for 5 days, for patients allergic to penicillin) and Tab.

Metronidazole (400 mg every 8 hrs for 5 days), analgesic Tab. Ibuprofen (400mg every 8 hrs for 5days), Chlorhexidine digluconate mouth rinses (0.2% twice for 2 weeks) and post surgical instructions.



**Fig.4: Placement of PRF in socket of study side**



**Fig.5: Primary closure of the wound**

Soft Tissue Healing- assessment by Landry<sup>4</sup> et. al.

#### ● Very poor

- Tissue color > or =50% of gingiva red.
- Response to palpation: bleeding.
- Granulation tissue: present.
- Incision margin: not epithelised, with loss of epithelium beyond incision margin.
- Suppuration present.

#### ● Poor

- Tissue color > or =50% of gingiva red.
- Response to palpation: bleeding.
- Granulation tissue: present.
- Incision margin: not epithelised, with Connective tissue exposed.

#### ● Good

- Tissue color : >or =25% and < 50% of

gingiva red.

- Response to palpation: no bleeding.
- Granulation tissue: none.
- Incision margin: no connective tissue exposed.

#### ● **Very good**

- Tissue color : < 25 % of gingiva red.
- Response to palpation: no bleeding.
- Granulation tissue: none.
- Incision margin: no connective tissue exposed.

#### ● **Excellent**

- Tissue color: all tissues pink.
- Response to palpation: no bleeding.
- Granulation tissue: none.
- Incision margin: no connective tissue exposed.

### **Radiographic assessment<sup>5,6</sup>**

#### **Lamina dura**

- +2 lamina dura essentially absent, may be present in isolated areas.
- +1 lamina dura essentially thinned, missing in some areas.

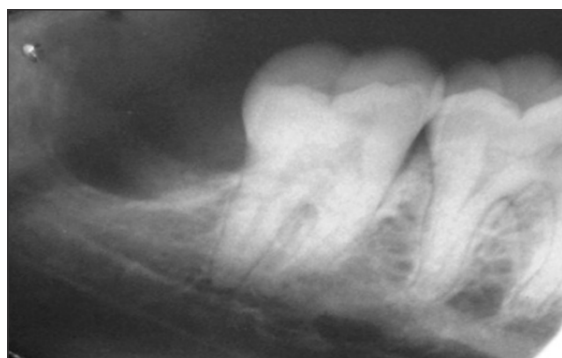
- 0 within normal limits.
- -1 portions of lamina dura thickened, milder degrees.
- -2 entire lamina dura substantially thickened.

#### **Overall density**

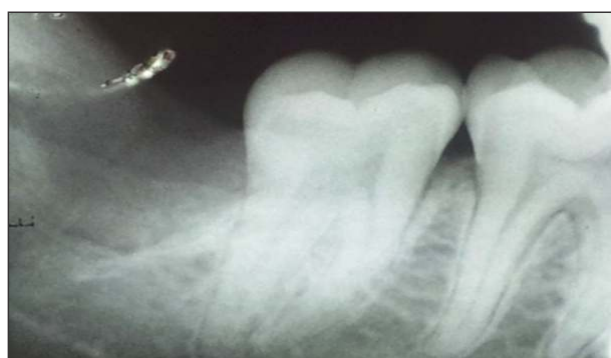- +2 severe increase in radiographic density.
- +1 mild to moderate increase in radiographic density.
- 0 within normal limits.
- -1 mild to moderate decrease in radiographic density.
- -2 severe decrease in radiographic density.

#### **Trabecular Pattern**

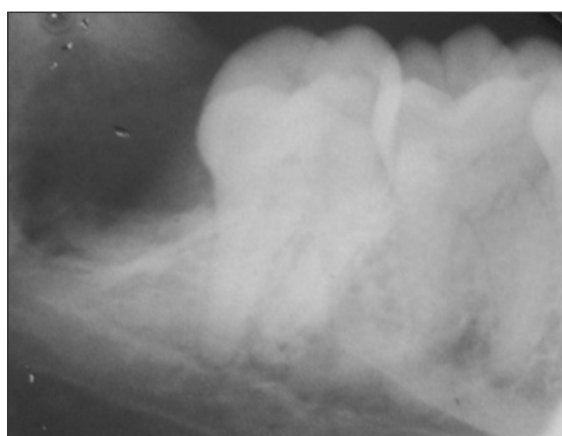
- +2 all trabeculae substantially coarser.
- +1 some coarser trabeculae to milder degrees.
- 0 within normal limits.
- -1 delicate finely meshed trabeculations.
- -2 granular, nearly homogenous patterns, individual trabeculations essentially absent.



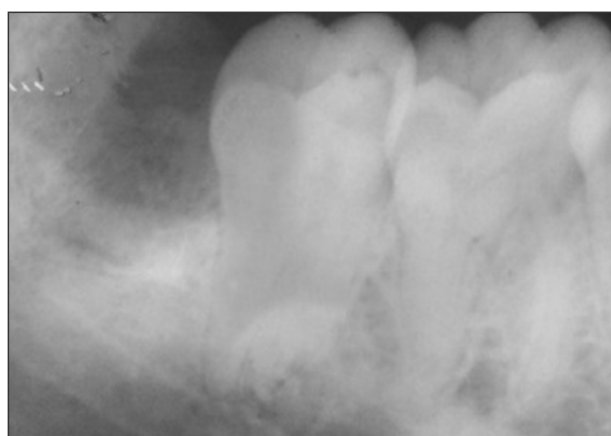
**Fig.6: Immediate post operative IOPA picture of socket**



**Fig.8: 2nd month postoperative IOPA**



**Fig.7: 1st month postoperative IOPA**



**Fig.9: 3rd month postoperative IOPA**

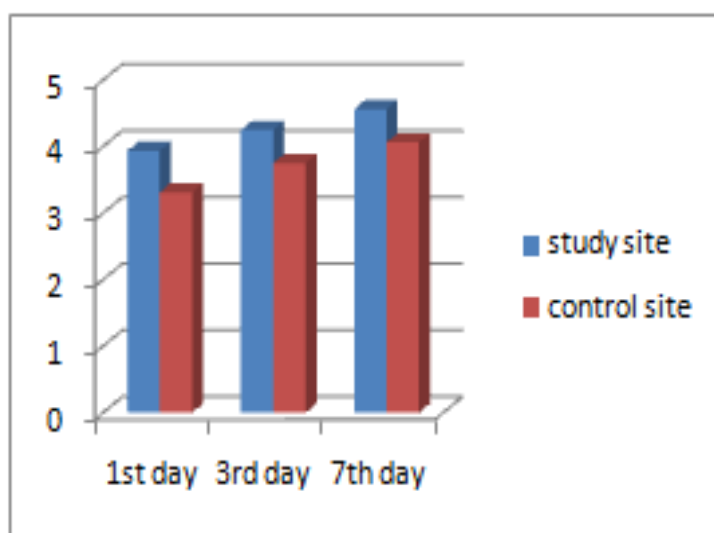
## Results

Statistical analysis showed that the mean difference in healing of the soft tissues on 1st day was 0.625 which has statistically highly significant (p 0.016). On 3rd postoperative day it was 0.500 which is statistically significant (p

0.048). On 7th postoperative day it was 0.500 which was statistically non significant (p 0.102). Hence, it can be concluded that soft tissue healing was better on the side grafted with autogenous PRF (Group I) as compared to the non grafted sites (Group II) which acted as control.

Group Statistics								
	Group	No.	Mean	Std. Deviation	Std. Error Mean	Mean Difference	p-value	Significance
Soft tissue healing (1st day)	Study site	16	3.9375	.57373	.14343	0.625	.016	HS
	Control	16	3.3125	.79320	.19830			
Soft tissue healing (3rd day)	Study site	16	4.2500	.57735	.14434	.50000	.048	S
	Control	16	3.7500	.77460	.19365			
Soft tissue healing (7th day)	Study site	16	4.5625	.62915	.15729	.50000	.102	NS
	Control	16	4.0625	.99791	.24948			

**Table 1-Difference in healing**



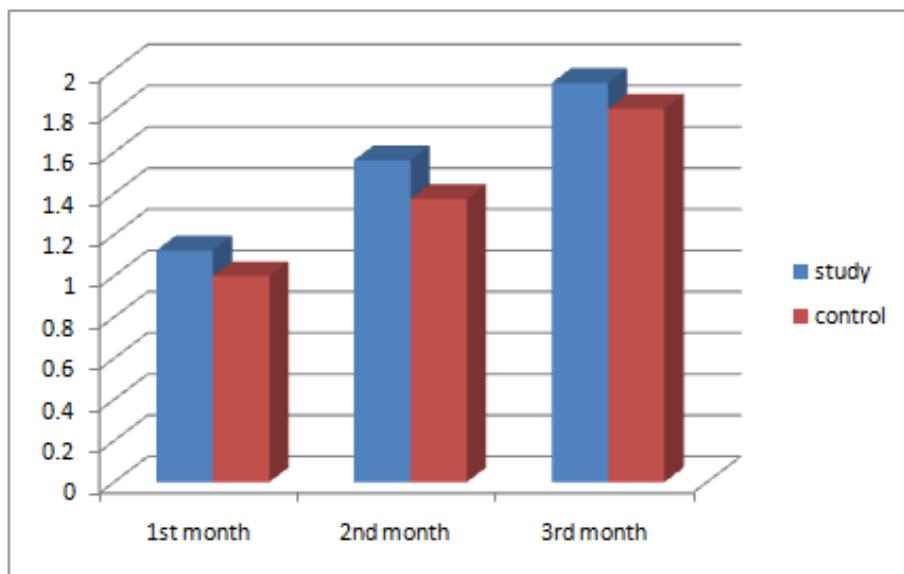
**Table 1-Difference in healing**

Statistical analysis showed that mean values of Lamina dura at the end of 1st, 2nd and 3rd postoperative months in Group I were  $1.12 \pm 0.34$ ,  $1.56 \pm 0.51$  and  $1.93 \pm 0.25$  respectively and in Group II they were  $1.00 \pm 0.00$ ,  $1.37 \pm 0.50$ ,  $1.81 \pm 0.40$  respectively. The mean difference in resorption rate of lamina dura in the two groups at the end of 1st, 2nd and 3rd month postoperatively

was 0.125 (p 0.164), 0.187 (p 0.303) and 0.125 (p 0.302) which was statistically non significant. It was concluded that lamina dura resorption and acceleration of formation of cortical bone in periphery of the sockets grafted with PRF was non significant as compared to the non grafted sockets during post operative period.

	Group	No.	Mean	Std. Deviation	Std. Error Mean	Mean Difference	p-value	Significance
<b>Lamina dura (immediate)</b>	Study site	16	.0000	.00000a	.00000	--	--	
	Control	16	.0000	.00000a	.00000			
<b>Lamina dura (1st month)</b>	Study site	16	1.1250	.34157	.08539	.12500	.164	NS
	Control	16	1.0000	.00000	.00000			
<b>Lamina dura (2nd month)</b>	Study site	16	1.5625	.51235	.12809	.18750	.303	NS
	Control	16	1.3750	.50000	.12500			
<b>Lamina dura (3rd month)</b>	Study site	16	1.9375	.25000	.06250	.12500	.302	NS
	Control	16	1.8125	.40311	.10078			

Table 2-Difference in lamina dura



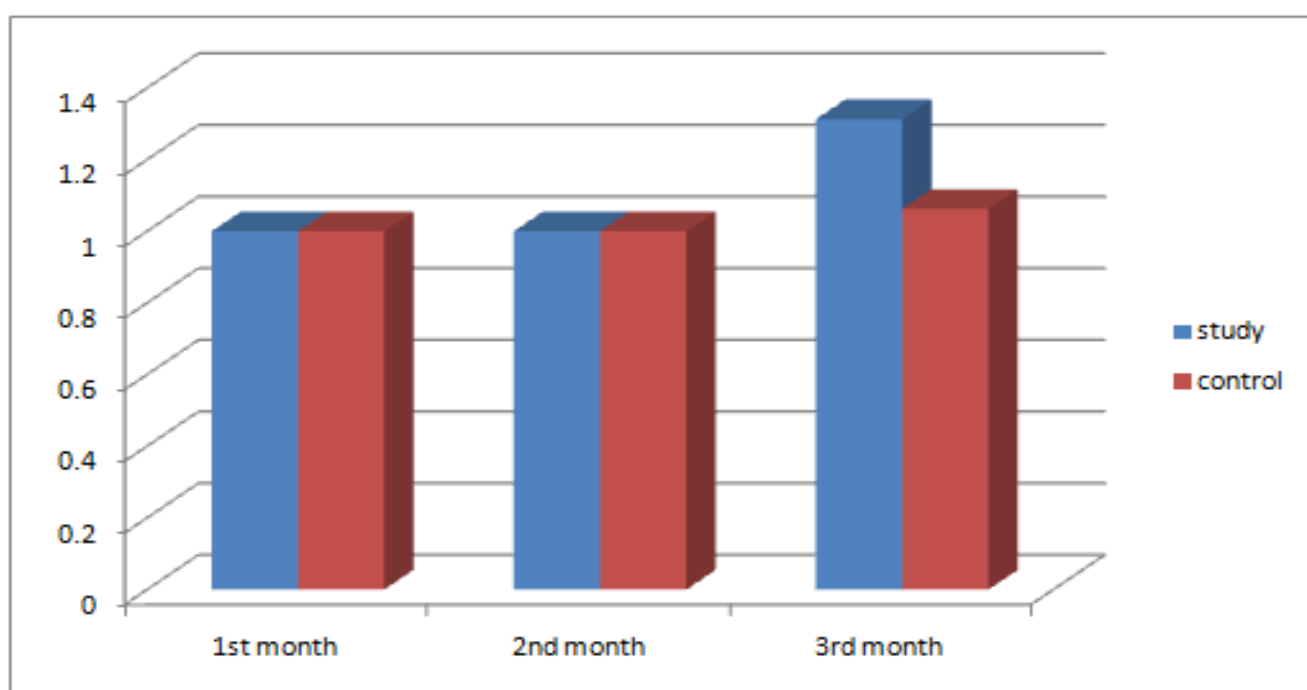
Graph 1-Difference in healing

Statistical analysis revealed that the scores of overall density in sockets of the site grafted with PRF was non significant as compared to the non grafted sockets during post operative period of 3

months, although it was observed that the rate of increase of overall density was more in PRF group as compared to control group.

	Group	No.	Mean	Std. Deviation	Std. Error Mean	Mean Difference	P-value	Significance
Density (immediate)	Study site	16	.0000	.00000a	.00000	--	--	
	Control	16	.0000	.00000a	.00000			
Density (1st month)	Study site	16	1.0000	.00000a	.00000	1.00	1.00	NS
	Control	16	1.0000	.00000a	.00000			
Density (2nd month)	Study site	16	1.0000	.00000a	.00000	1.00	1.00	NS
	Control	16	1.0000	.00000a	.00000			
Density (3rd month)	Study site	16	1.3125	.47871	.11968	.25000	.077	NS
	Control	16	1.0625	.25000	.06250			

**Table 3-Difference in density**



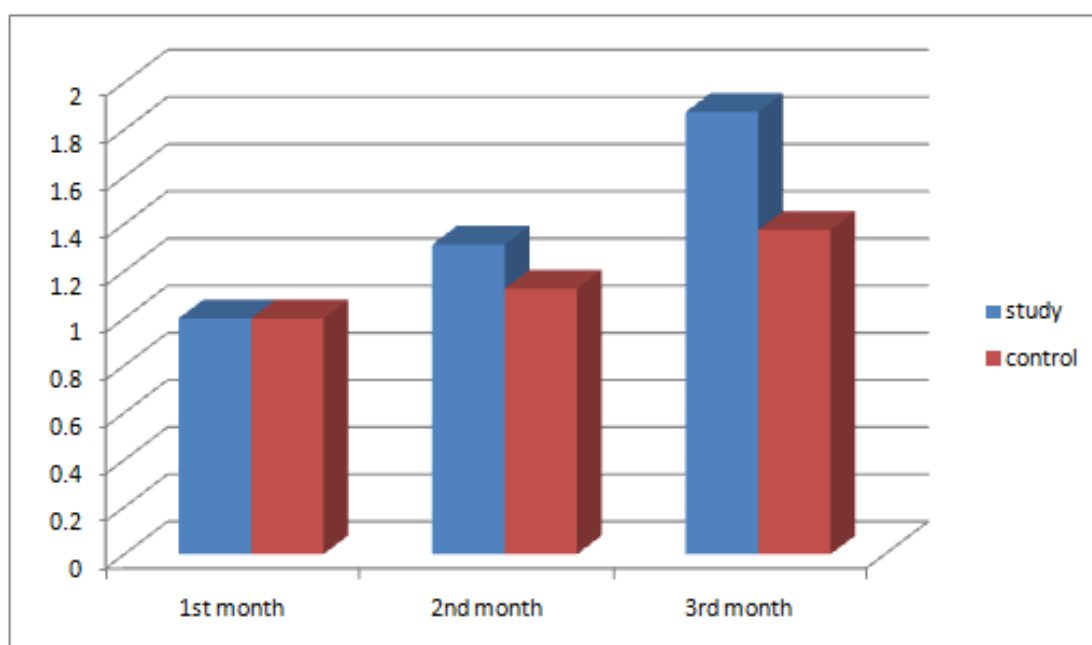
**Graph 3-Difference in density**

-Mean value related to trabecular pattern on end of 3rd postoperative month in Group I was  $1.87 \pm 0.34$  and in Group II was  $1.37 \pm 0.25$ . The mean difference in trabecular pattern was 0.500 which was statistically significant ( $p = 0.03$ ).

although the results were non significant for first two months, postoperatively. The difference in trabecular pattern showed significant increase at the end of 3rd month, postoperatively in the study group as compared to the control group

	Group	No.	Mean	Std. Deviation	Std. Error Mean	Mean Difference	p-value	Significance
Trabecular pattern (immediate)	Study site	16	.0000	.00000a	.00000	--	--	
	Control	16	.0000	.00000a	.00000			
Trabecular pattern (1st month)	Study site	16	1.0000	.00000a	.00000	1.00	1.00	NS
	Control	16	1.0000	.00000a	.00000			
Trabecular pattern (2nd month)	Study site	16	1.3125	.47871	.11968	.18750	.213	NS
	Control	16	1.1250	.34157	.08539			
Trabecular pattern (3rd month)	Study site	16	1.8750	.34157	.08539	.50000	.03	S
	Control	16	1.3750	.50000	.12500			
a. t cannot be computed because the standard deviations of both groups are 0.								

**Table 4-Difference in trabecular pattern**



**Graph 4-Difference in trabecular pattern**

## Discussion:

The majority of complications associated with third molar surgery are inflammatory with alveolitis and prolonged bleeding. It is assumed that growth factors can be used to promote wound healing which minimize postoperative complications and enhances bone regeneration, thereby improving patient comfort<sup>1</sup>.

The study of materials to promote bone regeneration is a key issue in oral surgery. Bone regeneration promotion can be done with variety of treatment modalities like bone substitute the use of autogenous bone grafts, guided tissue regeneration (GTR) with the use of barrier membranes and growth factors have been proposed to promote bone regeneration. Recently, Platelet Rich Fibrin (PRF) has come up as a second generation platelet concentrate with tissue regeneration properties and which is more biocompatible as well. It is a fibrin matrix in which platelets cytokines, growth factors and trapped cells are released enhancing healing and has excellent regeneration potential.

In this study, PRF was chosen as the sole grafting material without any additive material. It is assumed that the combination of bone grafts with PRF may give better results but the purpose of judgement of PRF as a sole grafting material would have been lost had any graft material been added to PRF in the extraction socket.

PRF is like a cell scaffold that can effectively direct the migration of stem cells to the wound, especially to induce epithelial cells to migrate to the wound surface and accelerate the healing process. In addition, PRF fibrin regulates the wound healing process by combining various growth factors, such as initial angiogenesis, epithelial coverage, and immune regulation. It also regulates the metabolism of fibroblasts and accelerates the healing of soft tissues. The concentration of platelets in PRF is 3-7 times higher than normal blood. The  $\alpha$ -granules in platelets can release a variety of growth factors that promote wound healing, such as epidermal growth, platelet-derived growth, vascular endothelial growth, which not only have synergistic effects, but other cell-promoting activities. These factors interact with each other, making soft tissue wounds heal faster and better whereas TGF- $\beta$ 1 promote new bone formation by stimulating collagen and fibronectin synthesis.<sup>19</sup>

In a study by Jiing-Huei Zhao et al,<sup>8</sup> Soft tissue healing was better on the side grafted with PRF.

Concurrent to our results similar clinical results were found, in which clinical healing occurred without any infectious episode nor untoward clinical symptoms. Taken together, the use of PRF for grafting may improve the clinical healing of a fresh extraction socket. Neovascularisation forms through the PRF clot and an epithelial covering develops in spite of the infections and inflammation of sockets. Rapid healing of the wound is observed without pain, dryness or purulent complications.<sup>2</sup>

A study conducted by Olufemi et al<sup>5</sup>, in this study radiographic assessment of bone regeneration is done to assess Lamina dura, overall density, and trabecular pattern scores, which were higher in the case group (grafted with PRF) compared with the control group (non grafted with PRF), indicating a greater bone density in the study group. This difference was not statistically significant between the two groups.

The use of platelet concentrates in oral and maxillofacial surgery; particularly in bone regeneration is a current and interesting trend. Various uses have been reported e.g. its use in fat graft<sup>17</sup>, sinus lift augmentation<sup>18</sup>, surgical healing enhancement of the extraction socket, gingival recession treatment<sup>4</sup>, filling up of intrabony defects, implant dentistry and bone regeneration<sup>3</sup> in pre prosthetic surgery etc.

## Conclusion

In this study, the clinical and radiological findings clearly indicate that PRF can be used as a sole graft material to improve soft tissue healing and bone regeneration. PRF has emerged as a promising material which can be used as a graft for socket preservation and its regeneration. It is concluded that application of the present study should be carried out with large sample size and longer duration follow up to get more informative and conclusive results.

## References

1. Antoine Diss, David M. Dohan et al: Osteotome sinus floor elevation using Choukroun's platelet-rich fibrin as grafting material: a 1-year prospective pilot study with microthreaded implants. *Oral Surg Oral Med Oral Pathol Oral Radiol Endod* 105: 572-9, 2008.
2. David MD, Choukroun J, Diss A, Dohan S L, Simonpieri A, Girard M D et al. Platelet-rich fibrin (PRF) : A second generation platelet concentrate. Part 4: Clinical effects on tissue healing. *Oral Surg Oral Med Oral Pathol Radiol Endod* 101: E56-60, 2006.
3. David M, Choukroun J. Platelet-rich fibrin (PRF): A

- second-generation platelet concentrate. Part 1: Technological concepts and evolution. *Oral Surg Oral Med Oral Pathol Oral Radiol Endod* 101: E37-44, 2006.
4. Sasha M jankovic, Aleksic M Zoran et al- The use of platelet- rich plasma in combination with connective tissue grafts following treatment of gingival recessions. *PERIO* 4(1):63-71, 2007.
5. Olufemi K. Ogundipe, Vincent I. Ugboko, Folusho j. Owotade- Can autologous platelet-rich plasma gel enhance healing after surgical extraction of mandibular third molars? *J Oral Maxillofac Surg* 69:2305-2310, 2011.
6. Kelley H. William, Mirahmadi K. Michael et al Radiographic changes of the jaw bones in end stage renal disease. *Oral surg, oral med, oral pathol, oral radiol, oral endod* 50:372, 1980.
7. Chen Yao Su, Ya Po Kuo, Yu Hong Tseng In vitro release of growth factors from platelet-rich fibrin (PRF): a proposal to optimize the clinical applications of PRF (*Oral Surg Oral Med Oral Pathol Oral Radiol Endod* 108:56-61, 2009.
8. Jiing-Huei Zhao, Chung-Hung Tsai et al Clinical and histologic evaluations of healing in an extraction socket filled with platelet-rich fibrin *Journal of Dental Sciences* 6:116, 2011.
9. Majid Eshghpour et al Effect of Platelet-Rich Fibrin on Frequency of Alveolar Osteitis Following Mandibular Third Molar Surgery: A Double-Blinded Randomized Clinical Trial. *J Oral Maxillofac Surg* 72:1463-1467, 2014.
10. Diss A, Dohan MD, Mouhyi J, Mahler P. Osteotome Sinus Floor Elevation Using Choukroun's Platelet-rich Fibrin as Graft Material: A 1-year Prospective Pilot Study With Microthreaded Implants. *Oral Surg Oral Med Oral Pathol Radiol Endod* 105:572-579, 2008.
11. Gurbuzer B, Pikdoken L, Tunah M, et al: Scintigraphic evaluation of osteoblastic activity in extraction sockets treated with platelet-rich fibrin. *J Oral Maxillofac Surg* 68:980, 2010.
12. Del Fabbro M, Brotolin M, Taschieri S: Is autologous platelet concentrate beneficial for post-extraction socket healing? A systematic review. *Int J Oral Maxillofac Surg* 40:891, 2011.
13. Kumar Nilima, Prasad Kavitha et al Evaluation of Treatment Outcome After Impacted Mandibular Third Molar Surgery With the Use of Autologous Platelet-Rich Fibrin: A Randomized Controlled Clinical Study *J Oral Maxillofac Surg* 73:1042-1049, 2015.
14. Yu-Chao Chang et al Clinical application of platelet-rich fibrin as the sole grafting material in periodontal intrabony defects. *Journal of Dental Sciences* 6, 181-88, 2011.
15. El-Sharkawy H, Kantarci A, Deady J, Hasturk H, Liu H, Alshahat M, et al. Platelet-rich plasma: growth factors and pro- and anti-inflammatory properties. *J Periodontol*. 78: 661-669, 2007.
16. Tomonori M, Kazuki K, Masashi T, Tazuko S, Chiaki A. Investigation of the procedure of PRP (Platelet-rich plasma) separation and gelatinization. Centrifugal conditions, and platelet activation with calcium chloride. *Oral Therapeutics and Pharmacology* 21(2):53-58, 2002.
17. Keyhan S. O. et al- Use of Platelet-Rich Fibrin and Platelet- Rich Plasma in combination with fat graft: which is more effective during facial liposuction? *J Oral Maxillofac Surg* 71:610-621, 2013.
18. Riaz R. et al- Efficacy of platelet Rich Plasma in Sinus Lift Augmentation. *J Maxillofac. Oral Surg.* 9(3):225-230, 2010.
19. Yiping Liu, Xiaolin Sun, Jize Yu, Jia Wang, Peisong Zhai, Siyu Chen, Manxuan Liu, and Yanmin Zhou. Platelet-Rich Fibrin as a Bone Graft Material in Oral and Maxillofacial Bone Regeneration: Classification and Summary for Better Application. *BioMed Research International* 19:1-16, 2019.