

## ASSESSMENT OF DRY SOCKET FORMATION AFTER SURGICAL REMOVAL OF IMPACTED MANDIBULAR THIRD MOLAR

\*Dr. Gagandeep Singh \*\*Dr. Hirdepal Singh Brar

\*Senior Lecturer, Department of oral surgery, Genesis institute of Dental Science and Research, Firozpur, Punjab

\*\*MDS, Oral Surgeon, Private consultant, Punjab

### Abstract

**Background:** Alveolar Osteitis (AO) is one of the most frequently encountered complications following mandibular third molar extraction. This study assessed the incidence and risk factors of dry socket following surgical removal of impacted mandibular third molar.

**Material & methods:** 120 patients planned for mandibular third molar extraction in the department of Oral & Maxillofacial surgery. Patients were recalled regularly and the prevalence of dry socket was recorded.

**Results:** Out of 120 patients, males were 70 and females were 50. Out of 70 males, 8 (11.4%) and out of 50 females, 6 (12%) had dry socket. 12 patients suffering from systemic diseases developed dry socket and 2 healthy patients had DS.

**Conclusion:** Incidence of dry socket formation are commonly seen in mandibular third molar extraction.

Key words: Alveolar osteitis, dry socket, Incidence

### Introduction

Dry socket (DS) or Alveolar Osteitis (AO) is one of the most frequently encountered complications following mandibular third molar extraction. It has been reported that the incidence of AO after the extraction of mandibular third molars is 10 times more than maxillary third molars.<sup>1</sup> The incidence of AO after mandibular third molar surgery varies between 5 to 30 percent in different studies. The two most common explanations as to why the mandibular third molar site is the most affected by dry socket are increased trauma and increased risk of bacterial contamination.<sup>2</sup> The exact etiology of AO is not well understood. Birn suggested that the etiology of AO is an increased local fibrinolysis leading to disintegration of the clot. However, several local and systemic factors are known to be contributing to the etiology of AO.<sup>3</sup>

Severe, debilitating, constant pain that continues through the night, becoming most intense at 72 hours post-extraction are common symptoms in patients. It can be associated with foul taste and halitosis. The pain responds poorly to over-the-counter analgesic medication. Clinically, an empty socket (lacking a blood clot) with exposed bone is seen. Other symptoms include low

grade fever and regional lymphadenopathy.<sup>4</sup> This study assessed the incidence and risk factors of dry socket following surgical removal of impacted mandibular third molar.

### Material & methods

This study was conducted among 120 patients planned for mandibular third molar extraction in the department of Oral & Maxillofacial surgery. All enrolled patients were informed regarding the study and their written consent was obtained.

Data such as name, age, gender etc. was recorded. Third molar extraction was performed following all standardized procedures. After procedure 4 mg of corticosteroid was administered intravenously and all patients were given combination of 50 mg Diclofenac sodium and 500 mg Paracetamol and 500 mg Amoxicillin TID for 5 days. They were instructed strictly to bite firmly for 30 minutes, on sterile gauge placed over the wound, to avoid rinsing for the next 24 hrs, to take cold liquids for the first 24 hrs followed by warm saline rinses and 0.2% chlorhexidine rinses intermittently after 24 hrs to keep the area clean of any debris and to avoid tobacco intake for at least 7 days after the surgery. Patients were recalled regularly and the prevalence of dry socket was recorded.

## Results

Table I Distribution of patients

Total- 120		
Gender	Males	Females
Number	70	50

Table I shows that out of 120 patients, males were 70 and females were 50.

Table II incidence of Dry socket

Total	Incidence DS	Percentage
Males	8	11.4%
Females	6	12%

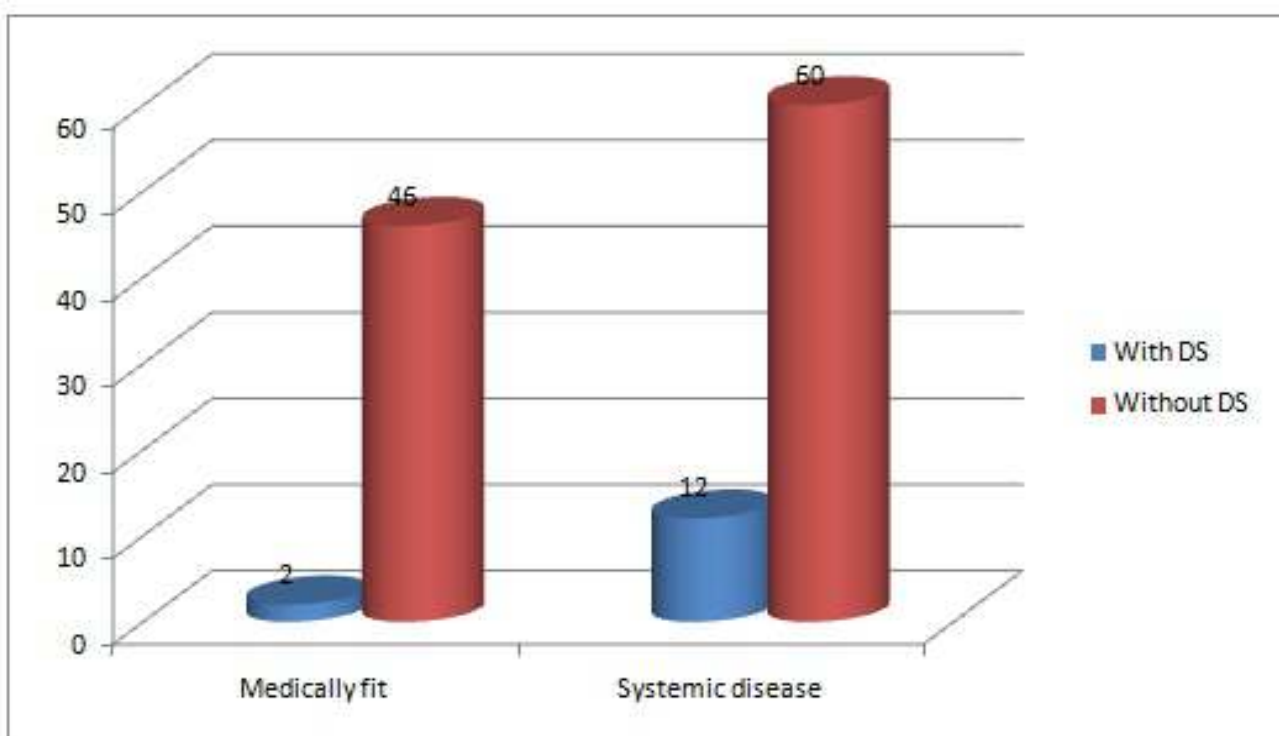
Table II shows out of 70 males, 8 (11.4%) and out of 50 females, 6 (12%) had dry socket.

Table III Association between medical status and incidence of DS

Systemic status	With DS	Without DS	P value
Medically fit	2	46	0.01
Systemic disease	12	60	

Table III, graph I shows that 12 patients suffering from systemic diseases developed dry socket and 2 healthy patients had DS.

Graph I Association between medical status and incidence of DS



## Discussion

Dry socket is the most common complication after surgical removal of impacted mandibular third molars. The incidence of AO is 10 times more in mandible when compared to maxilla ranging from 1 to 4% of extractions, reaching 45% for mandibular third molars. AO may affect women in ratio of 5:1 with respect to males.<sup>5</sup> Due to changes in endogenous estrogens during the menstrual cycle since estrogens activate the fibrinolytic system in an indirect way in females. On average, a time period of 7 to 10 days is required for exposed bone to become covered with new granulation tissue, and efforts must be made to relieve patient discomfort during this period.<sup>6</sup> Turner used reflection of flap, removal of bone particles, curettage and removal of granulation tissue with irrigation and found that this method required fewer visits than ZOE pack. Research recommended gentle irrigation with warm saline under local anesthesia before application of ZOE dressing with iodoform ribbon gauze.<sup>7</sup> The packing should be changed every 2 to 3 days and removed once pain is reduced. Choice of analgesics varies from short course of NSAID'S drugs to narcoticbased preparations such as acetaminophen with codeine, hydroxycodone or oxycodone.<sup>8</sup> This study assessed the incidence and risk factors of dry socket following surgical removal of impacted mandibular third molar.

In present study, out of 120 patients, males were 70 and females were 50. We found that out of 70 males, 8 (11.4%) and out of 50 females, 6 (12%) had dry socket. Qadus et al<sup>9</sup> assessed the prevalence of dry socket in association with gender, site and age. This study includes hundred consecutive patients with dry socket coming to the OPD at Oral Surgery Department. A comprehensive proforma was formulated and filled for comparison of gender, age and site in relation to dry socket. The results of this comparative study were analyzed through chi-square test. Females were 2.37 times more prone to dry socket as compared to males. Whereas, dry socket was found 2.94 times more common in mandibular extractions as compared to

maxillary. It was less common in young age group (18%) as compared to older patients (67%).

We observed that 12 patients suffering from systemic diseases developed dry socket and 2 healthy patients had DS. Blum I. R10 found that dry socket patients had at least two of the following signs and symptoms: that is empty socket, pain in or around the socket, with or without halitosis. Akinbami et al<sup>11</sup> in their study on one thousand, one hundred and eighty two patients with total of 1362 teeth extracted during the 4-year period of the study were analyzed, out of which 1.4% teeth developed dry socket. The mean age (SD) was 35.2 (16.0) years. Most of the patients who presented with dry socket were in the fourth decade of life. Mandibular teeth were affected more than maxillary teeth. Molars were more affected. Retained roots and third molars were conspicuous in the cases with dry socket. The incidence of dry socket in our centre was lower than previous reports. Oral hygiene status, lower teeth, and female gender were significantly associated with development of dry socket. Treatment with normal saline irrigation and ZnO eugenol dressings allowed relief of the symptoms.

## Conclusion

Authors found that incidence of dry socket formation are commonly seen in mandibular third molar extraction.

## References

1. Bloomer CR. Alveolar osteitis prevention by immediate placement of medicated packing. *Oral Surg Oral Med Oral Pathol Oral Radiol Endod* 2000; 90:282-4.
2. Sisk AL, Hammer WB, Shelton DW. Complication following removal of impacted third molars: The role of the experience of the surgeon. *J Oral Maxillofac Surg* 1986;44:855-9.
3. Birn H. Etiology and pathogenesis of fibrinolytic alveolitis (dry socket). *Int J Oral Surg* 1973;2:215-63.
4. Heasman PA, Jacobs DJ. A clinical investigation into the incidence of dry socket. *Br J Oral Maxillofac Surg* 1984;22:115-22.
5. Larsen, P.E. Alveolar osteitis after surgical re-moval of impacted mandibular third molars: Identifica-tion of the patient at risk. *Oral Surgery, Oral Medicine, Oral Pathology* 1992; 73: 393-397.
6. Lilly GE, Osborn DB, Rael EM, Samuels HS, Jones JC. Alveolar osteitis associated with mandibular third molar extractions. *J Am Dent Assoc* 1974; 88: 802-6.

7. Garcia AG, Grana PM, Sampedro FG, Diago MP, Rey JM. Does oral contraceptive use affect the incidence of complications after extraction of a mandibular third molar? *Br Dent J* 2003;194: 453-5.
8. Qadus A, Qayyum Z, Katpar S, SALAM SA. Prevalence of dry socket related to gender and site. *Pakistan Oral & Dental Journal*. 2012 Jun 1;32(1).
9. Meechan JG, Macgregor ID, Rogers SN, Hobson RS, Bate JP, Dennison M. The effect of smoking on immediate post-extraction socket filling with blood and on the incidence of painful socket. *Br J Oral Maxillofac Surg* 1988;26:402-9.
10. Blum IR. Contemporary views on dry socket (alveolar osteitis): a clinical appraisal of standardization, aetiopathogenesis and management: a critical review. *Int J Oral Maxillofac Surg* 2002;31:309-17.
11. Akinbami BO, Godspower T. Dry socket: incidence, clinical features, and predisposing factors. *International journal of dentistry*. 2014 Jun 2;2014